



Experimental Study

Effect of long term-administration of aspartame on the ultrastructure of sciatic nerve



Ebtsam F. Okasha*

Histology Department, Faculty of Medicine, Tanta University, Tanta, Egypt

ARTICLE INFO

Article history:

Received 29 July 2015

Received in revised form 13 January 2016

Accepted 5 February 2016

Available online 15 February 2016

Keywords:

Aspartame
Sciatic nerve
Ultrastructure

ABSTRACT

Aspartame is the most widely used artificial sweetener worldwide. There is much controversy about the effect of aspartame on different cells in the body. The aim of this study was to evaluate the effect of aspartame on the structure of the sciatic nerve. Thirty adult male albino rats were divided into three groups. Group I served as control; Group II received aspartame orally in a dose of 250 mg/kg/d for 3 months; Group III received aspartame at the same dose and for the same period, and was allowed to recover for 1 month. Specimens of sciatic nerve were processed, and semithin and ultrathin sections were examined by light and electron microscopy. A morphometric study was done to evaluate the g-ratio, which is the ratio between the axon diameter and total fiber diameter. Long-term aspartame administration resulted in many degenerative changes affecting mainly the myelin sheath, in the form of focal and extensive demyelination; disruption and splitting of myelin lamellae with loss of compact lamellar structure; and excessive enfolding with irregular thickening of myelin sheaths. Less frequent than those observed in the myelin sheath, some axonal changes were detected, such as compression and distortion. Dilated rough endoplasmic reticulum and vacuolation of the cytoplasm of Schwann cells were also detected. Partial improvement was observed in the recovery group. It was concluded that long-term administration of aspartame had a harmful effect on the structure of sciatic nerve and 1 month stoppage of aspartame was not enough to achieve complete recovery.

© 2016 Published by Elsevier Ltd. on behalf of Saudi Society of Microscopes.

1. Introduction

Aspartame is an artificial sweetener consumed by > 200 million people worldwide and it is used as non-nutritive sweetener in ~6000 food products, including dry beverage mixes, chewable multi-vitamins, breakfast cereals, chewing gum, puddings and fillings, carbonated beverages, refrigerated and nonrefrigerated ready to drink beverages, yoghurt products, and pharmaceuticals [1].

It has been found that aspartame induces toxicity at various levels. Recently, many experimental studies have

confirmed that aspartame is a multipotential carcinogenic agent and increases the risk of lymphoma, leukemia, urinary tract tumors, and neurological tumors, even at a daily dose (20 mg/kg) that is much less than the acceptable daily dose (40 mg/kg) [2]. In addition, several studies have suggested an association between aspartame consumption and the risk of type 2 diabetes [3], preterm delivery [4], nephrotoxicity [5], hepatotoxicity [6], and induction of histopathological changes in the parotid salivary glands [7].

With regard to neurotoxicity of aspartame, most of the previous studies were concerned about central nervous system toxicity. Aspartame affects the cerebral cortex [8] and cerebellar cortex [9,10], affecting memory, learning, and behavior [11]. The aim of the present study was to

* Corresponding author. Histology Department, Faculty of Medicine, Tanta University, Tanta, Egypt.

evaluate the effect of aspartame on the structure of the sciatic nerve in adult male albino rats.

2. Materials and methods

2.1. Preparation of animals and study design

The present study was carried out on 30 adult male albino rats, weighing 150–200 g. The animals were kept in adequate ventilation and temperature and were fed standard laboratory food and water. The rats were divided into three equal groups. Group I (Control Group) received ordinary diet and water. Group II (Aspartame Group) received aspartame (250 mg/kg/d) [12] dissolved in distilled water and administered by gastric tube for 3 months. This dose corresponded to the acceptable daily intake in humans (defined by the World Health Organization) of 40–50 mg/kg/d. Species correction required a five to six times higher dose in rats than humans, as rats metabolize aspartame faster than humans [13]. Group III (Recovery Group) received aspartame as in Group II, but rats were left for 1 month after stopping aspartame to recover before they were killed.

2.2. Preparation for microscopy

Samples from the sciatic nerves were obtained at the end of the experiment. Rats were killed by decapitation and the sciatic nerves were carefully dissected out, sectioned transversely into small pieces of 1 mm² and fixed in 2.5% glutaraldehyde for 24 hours. Specimens were washed in 0.1 M phosphate buffer at 4 °C, then postfixed in 1% osmium tetroxide at room temperature. Specimens were dehydrated in ascending grades of ethanol, and embedded in Epon resin (Embed; pure Epon/Araldite mixture) for 24 hours at 35 °C, 48 hours at 45 °C, and 24 hours at 60 °C (gradual method) (Mammalian Soft Tissue Protocol - In-situ and Immersion fixation) then place labels into BEEM (Better Equipment for Electron Microscopy) capsules, add degassed resin, and then add tissue blocks. Tissue blocks descended to the tip of the BEEM capsules before polymerization of resin. Semithin sections (1 μm) were stained with toluidine blue and examined by light microscopy. Ultrathin sections were cut, mounted on copper grids, and stained with uranyl acetate and lead citrate [14]. Specimens were examined and photographed with a JEM transmission electron microscope.

2.3. Morphometric and statistical study

Using a Leica LAS software program (Leica Geosystems, St. Gallen, Switzerland) connected to a microscope (Leica Microsystems, Wetzlar, Germany), the diameter of the regular myelinated fibers of the sciatic nerve and their axons in five nonoverlapping fields was measured manually, and then the axon/fiber ratio was estimated, which is known as the g-ratio [15]. Morphometric data were analyzed, and differences were considered significant at $p \leq 0.05$. Morphometric study was carried out at the Image Analysis Unit, Faculty of Medicine, Tanta University, Tanta, Egypt.

3. Results

3.1. Light microscopy

Toluidine-blue-stained sections of the sciatic nerve of the Control Group revealed normal histological features for nerve axons, myelin coat, Schwann cells, and endoneurium (Figures 1A and 1B). Examination of the Aspartame Group revealed increased spaces between the nerve fibers, and the endoneurium contained dilated blood vessels with multiple cells with irregular nuclei (Figures 1C and 1D), in addition to focal lysis of some myelin sheaths and formation of myelin loops (Figure 1E). Marked demyelination, degeneration (Figure 1F), and irregular thickening (Figure 1G) of myelin sheaths were also detected. In the Recovery Group, toluidine-blue-stained sections revealed partial improvement. Some fibers appeared similar to those of the Control Group, while others showed irregularity of the myelin sheath with focal lysis (Figure 1H).

3.2. Electron microscopy

Ultrathin sections of the Control Group revealed Schwann cells surrounded by myelinated and unmyelinated axons. Myelinated axons were surrounded with regular myelin sheaths with preserved compact lamellar structure and uniform thickness, and the axoplasm contained multiple microtubules and mitochondria (Figures 2A and 2B). Ultrathin sections of the sciatic nerve of the Aspartame Group showed many monocytes with their distinctive nuclei, which were indented, kidney-shaped, or C-shaped, within dilated blood vessels (Figures 2C and 2D), in addition to marked degenerative changes affecting mainly the myelin coat. Most samples showed focal lysis of myelin sheaths (demyelination; Figure 2E) with redundant myelin (Figures 2F and 2G) and formation of myelin loops (invagination of myelin sheaths toward the axoplasm); Figure 2H), incisures (wide separations) of myelin lamellae and splitting (loss of compact lamellar structure; Figures 3A and 3B). Some nerve fibers with marked disruption (discontinuous and disorganization), demyelination, and degeneration of the myelin sheath were also detected (Figures 3C and 3D). However, excessive enfolding with irregular thickening of the myelin sheaths was detected in some areas (Figures 3E and 3F). Changes in axons were less frequent than those observed in the myelin sheath; some axons appeared shrunken and compressed with distorted axoplasm (Figures 3E and 3F). Regarding the Schwann cell coat, the most prominent findings were destroyed swollen mitochondria, dilated rough endoplasmic reticulum (RER), in addition to vacuolation of the cytoplasm (Figures 3G and 3H). Examination of ultrathin sections obtained from the Recovery Group revealed partial improvement, with some fibers appearing similar to those in the Control Group (Figures 4A and 4B). Some fibers showed focal lysis, focal appearance of redundant myelin, focal separation of the myelin sheath from the axon, and the axoplasm of some nerve fibers contained few vacuoles (Figures 4C–4H).

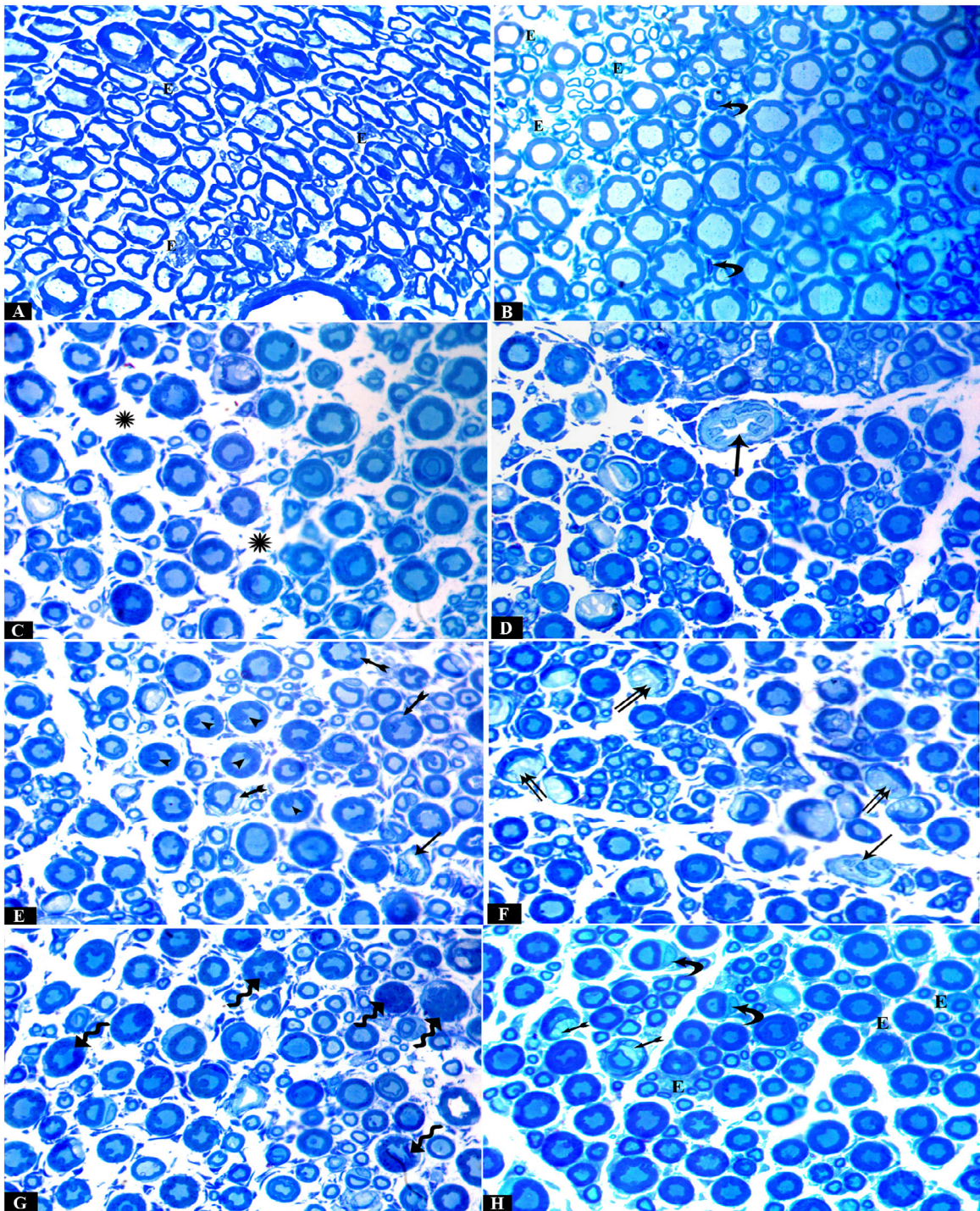


Fig. 1. Photomicrographs of toluidine-blue-stained semithin sections of rat sciatic nerve. (A, B) Control Group showing myelinated nerve fibers of various sizes with endoneurium (E) in between. (C–G) Aspartame Group showing (C) increased spaces (star) in between nerve fibers, (D–F) dilated blood vessel (arrow) containing many cells with irregular nuclei, (E) multiple myelin loops (arrow heads) and focal lysis of myelin sheath (bifid arrow) of some fibers, (F) excess demyelination and degeneration of myelin sheath (double arrow) in other fibers, and (G) irregular myelin thickening (waved arrow) in many nerve fibers. (H) Recovery Group showing nearly normal myelinated nerve fibers, Schwann cells (curved arrow) and endoneurium (E) in control group with some focal lysis (bifid arrow). Toluidine blue, 1000 \times .

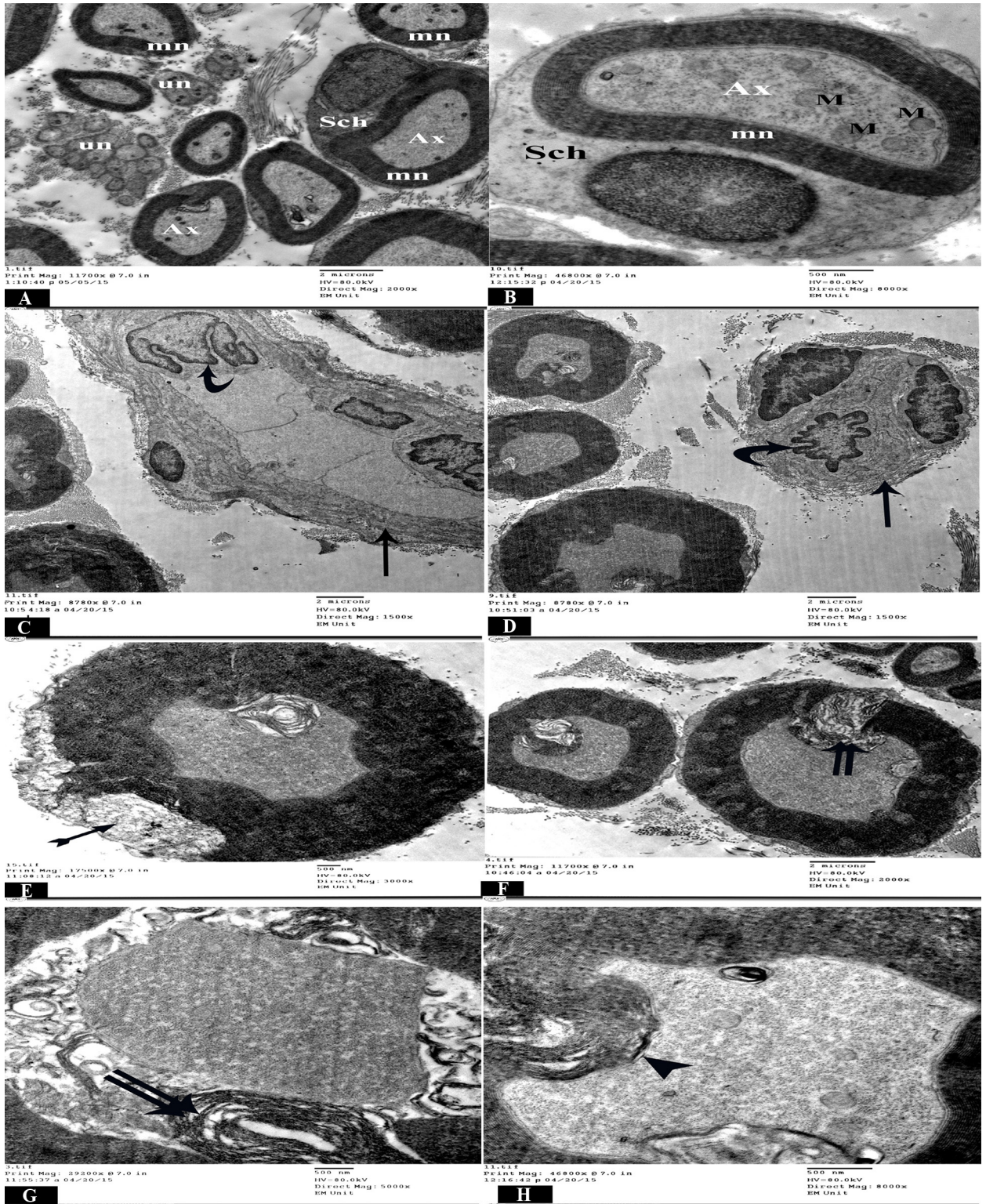


Fig. 2. Electron micrographs of ultrathin sections of rat sciatic nerve of the (A, B) Control Group showing, normal myelinated (mn) and unmyelinated (un) nerve fibers, and axoplasm (Ax) of myelinated fibers containing multiple microtubules and mitochondria (M), that are wrapped in a thick myelin sheath with compact lamellar structure and surrounded by Schwann cells (Sch). (C–H) Aspartame Group showing blood vessels (arrow) lined by endothelial cells and containing (C, D) monocytes with irregular nuclei (curved arrow), (E) focal lysis (bifid arrow) of myelin sheath with (E, F) appearance of redundant myelin (double arrow) and (G, H) formation of myelin loop (arrow head).

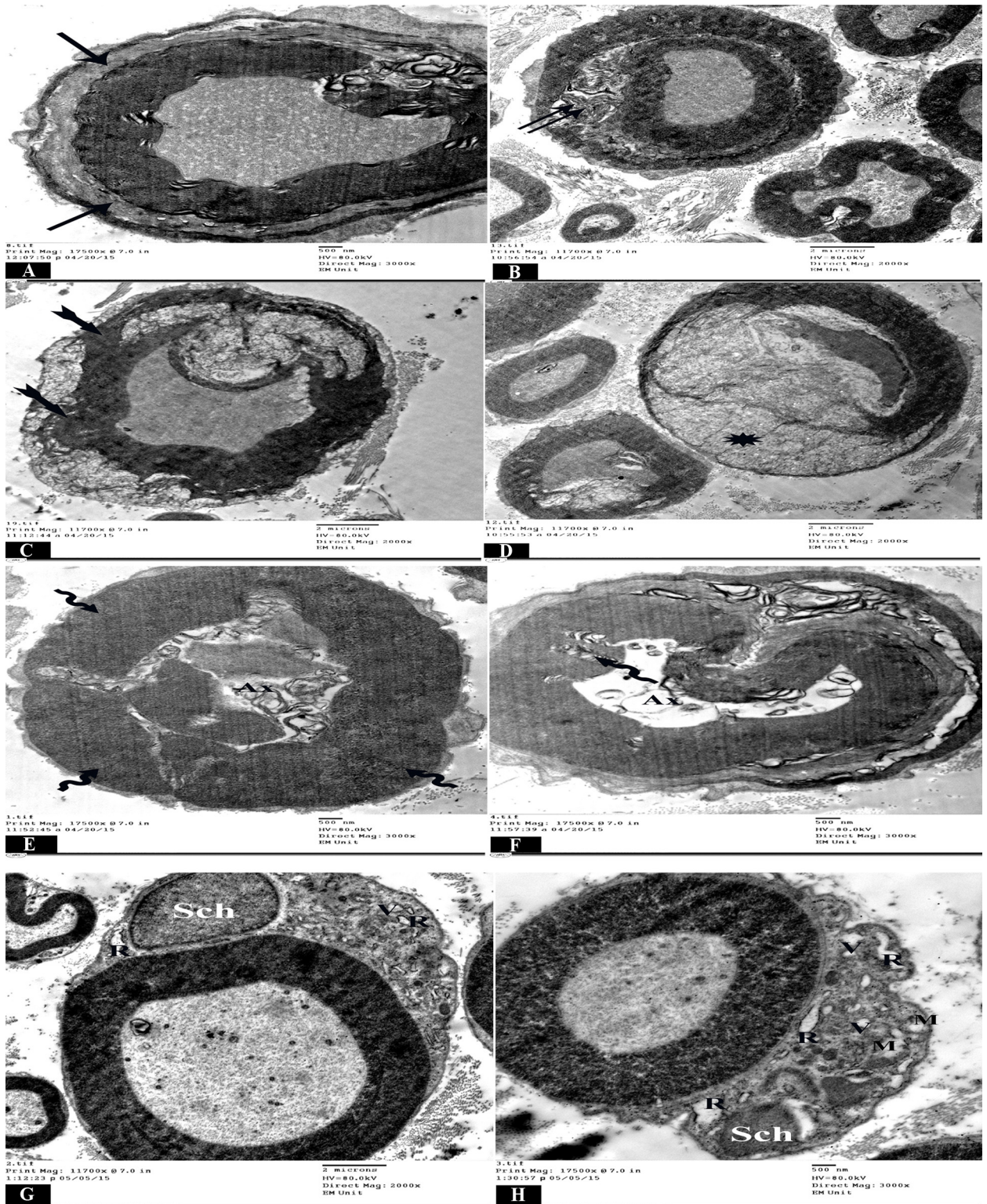


Fig. 3. Electron micrographs of ultrathin sections of rat sciatic nerve of Aspartame Group showing (A) separation (incisures) of myelin lamellae (arrow) with (B) focal loss of compact lamellar structure (splitting) of myelin sheath (double arrow), (C) discontinuous and disorganized myelin sheath (bifid arrow) with (D) marked lysis (star), (E, F) abnormal and irregular thickening of myelin (waved arrow), with compressed distorted axoplasm (Ax), (G, H) Schwann cells (Sch) with swollen and destroyed mitochondria (M), dilated rough endoplasmic reticulum (R), and vacuolation (V) of the cytoplasm.

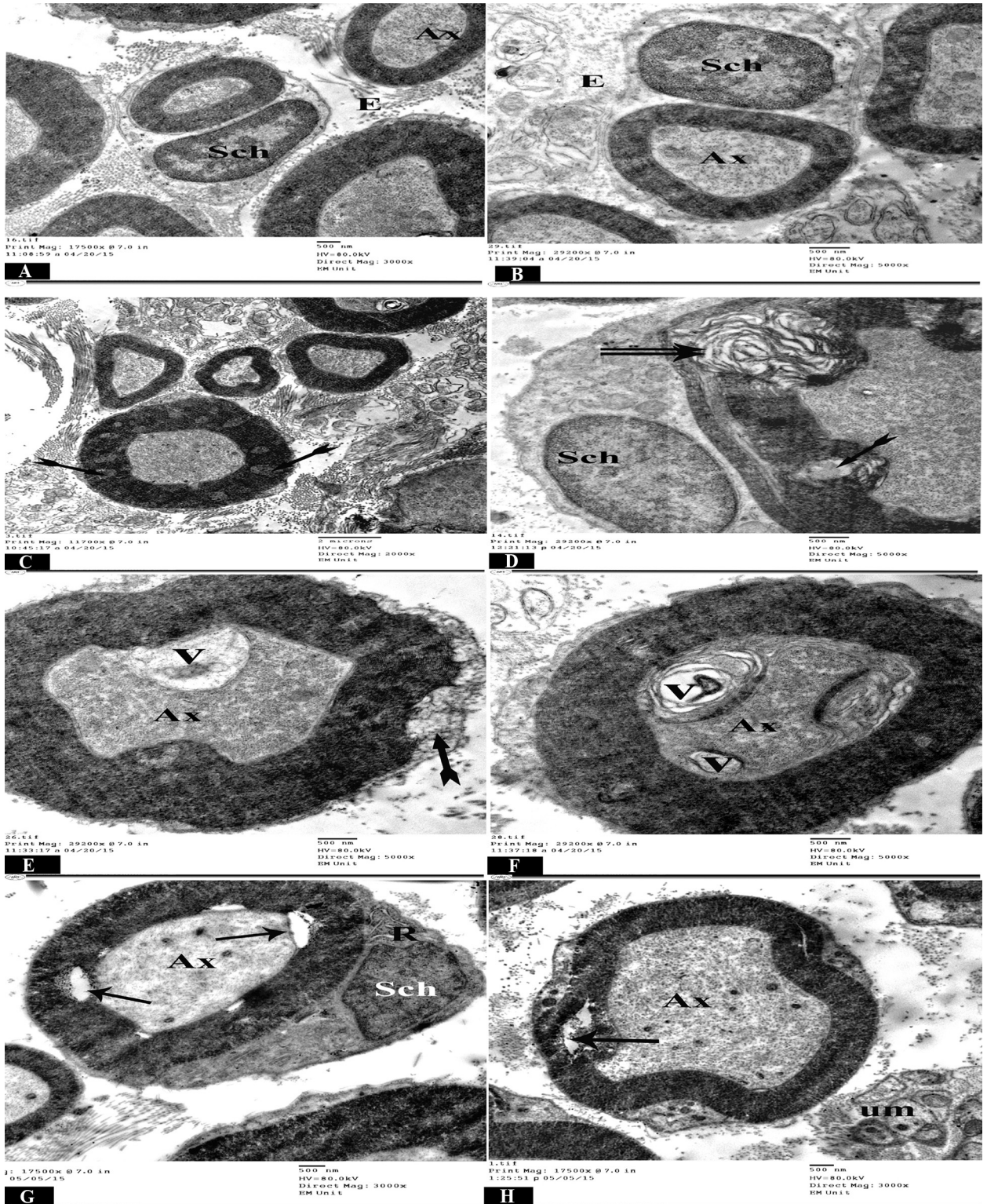


Fig. 4. Electron micrographs of ultrathin sections of rat sciatic nerve of the Recovery Group showing (A, B) multiple axons (Ax) with normal appearance and endoneurium (E) in between, surrounded by myelin sheath and Schwann cells (Sch), with (C–E) some focal lysis (bifid arrow), (D) focal appearance of redundant myelin (double arrow), and (E, F) membrane-bound vacuoles (V) in some axons (Ax) with (G, H) separation (arrow) of myelin sheath from the axon at some sites.

Table 1
Mean g-ratio and SD in the different groups.

Group	Control	ASP	Recovery
Mean A/F ratio	0.594	0.324	0.490
SD	± 0.068	± 0.085	± 0.067
p	—	0.0001	0.53

A/F = axon/fiber ratio (g-ratio); ASP = aspartame; SD = standard deviation.

3.3. Morphometric and statistical studies

The data were analyzed by one-way analysis of variance followed by analysis using SPSS version 11.5 (SPSS Inc., Chicago, IL, USA). All values were expressed as mean ± standard deviation. Table 1 and Figure 5 show that the mean values of axon/fiber ratio (g-ratio) in the Control Group, Aspartame Group, and Recovery Group were 0.594 ± 0.068 , 0.324 ± 0.085 , and 0.490 ± 0.067 , respectively. There was a highly significant decrease in the mean value in the Aspartame Group ($p < 0.0001$) as compared with the Control Group, and there was a nonsignificant decrease ($p > 0.05$) in the Recovery Group as compared with the Control Group.

4. Discussion

Aspartame and its amino acid isolates have been implicated as causes of neurodegenerative diseases such as Alzheimer's disease, Parkinsonism, multiple sclerosis, and seizures [16]. Everyday consumption of aspartame is increasing, therefore, further investigations are recommended to confirm or allay existing fears concerning aspartame.

In the present work, the effect of long-term aspartame administration on the sciatic nerve was studied. Our results showed that aspartame administration to rats resulted in many histopathological and degenerative changes affecting mainly the myelin sheaths, in the form of focal and extensive demyelination; disruption and splitting of myelin lamellae, with loss of compact lamellar structure; formation of myelin loops; and excessive enfolding with irregular thickening of myelin sheaths. Less frequent than those observed in the myelin sheath, some axons appeared shrunken, compressed, and distorted, with

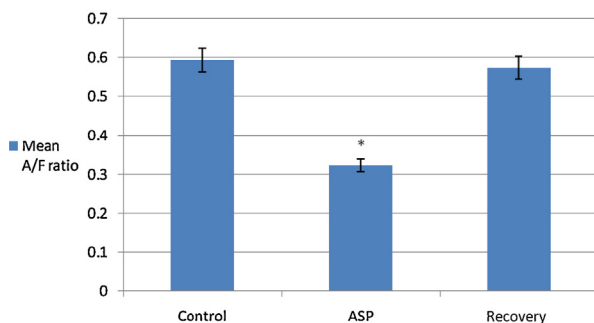


Fig. 5. Histogram showing the mean value of the axon/fiber (A/F) ratio (g-ratio) in the sciatic nerve of different groups.

* $p < 0.0001$ is highly significant versus control group.

ASP = aspartame.

destroyed swollen mitochondria, in addition to dilatation of RER and vacuolation of the cytoplasm of Schwann cells.

In the present study, long-term administration of aspartame induced neurotoxic effects and major ultrastructural changes in the sciatic nerve. Several possible mechanisms were considered to be involved in the neurotoxic effects of aspartame. It is reported that, after ingestion of aspartame, it is metabolized in the gastrointestinal tract into triple toxins: aspartic acid, phenylalanine, and methanol and further breakdown products including formaldehyde and formic acid [17]; the latter is considered to be the principal metabolite responsible for the deleterious effects of acute intoxication by methanol in humans and animals [18]. A small amount of aspartame significantly increases plasma methanol, formaldehyde, and formate levels, and these processes are accompanied by the formation of superoxide anion and hydrogen peroxide [19]. These alterations may contribute to increased production of free radicals [20] that can cause membrane damage through peroxidation of unsaturated fatty acids in the phospholipids of the cell membrane, accompanied by altered structural and functional characteristics of membranes [21]. They can also cause damage to fundamental cellular components such as nucleic acid lesions, gene damage, and gene repair activity, leading to subsequent cell death by necrosis or apoptosis [22]. Antioxidant depletion or deficiency may contribute to oxidative stress that results from an oxidant/antioxidant imbalance. Oxidative stress is thought to play an important role in cell injury [23].

Glutamate and aspartate are two of the most common neurotransmitters normally found in the brain and spinal cord, and when their concentrations rise above a critical level, they become neurotoxic (excitotoxins). More recent molecular studies have explained the mechanism of neuronal destruction and neurotoxicity of aspartame. Aspartame and other excitatory amino acids activate calcium channels via a specialized family of receptors that act as the gatekeeper of the calcium channel on the cell membrane and regulate the entry of calcium into the neurons. This calcium further triggers a cascade of reactions, including free-radical generation and lipid peroxidation, which destroy the cells. With this calcium-triggered stimulation, the neurons become excited, firing impulses repetitively until cell death, hence the name excitotoxins [24].

Myelin sheath abnormalities observed in the present study, such as wide incisures, separation of lamellae, and myelin loops, which are common features of axonal atrophy, and variations in myelin thickness can influence the maintenance of a circular shape of myelinated fibers [25], while demyelination was explained in some studies as the oxidative stress may impair the axonal membrane, leading to demyelination [26]. In terms of peripheral neuropathy, the protein glycation cascade may lead to demyelination or axonal atrophy; glycation of the myelin proteins could account for myelin destruction and consequent demyelination; and glycation of collagen and laminin could lead to reduced nerve growth factor, and axonal atrophy [27].

Myelin loops have been described during the first stages of development and interpreted as a step in the process of myelin recycling. However, the increased frequency of myelin loop formation is related to an early response

of large-caliber myelin sheaths to axonal atrophy. Some authors have mentioned that formation of infolded myelin loops is a characteristic response of large-caliber myelin sheaths to axonal atrophy, and probably reflects the presence of redundant myelin [28].

Mitochondrial degeneration and cytoplasmic vacuolation of Schwann cells have been explained by previous investigators [9] who demonstrated vacuoles in the cytoplasm of pyramidal cells of the frontal cortex of rats after 8 weeks of aspartame administration. It is concluded that aspartame metabolism leads to the generation of many free radicals, such as nitrogen and oxygen species [29]. These free radicals have been shown to damage cellular proteins and DNA. Other researchers have shown that the most immediate DNA damage was to that of the mitochondria [8]. This leads to increased permeability of the membranes and disturbance of the ion concentration in the cytoplasm and organelles. Such damage is specifically followed by an increase in the plasma membrane permeability to sodium, which exceeds the capacity of the pump to extrude sodium. Accumulation of sodium leads to an increase in water content in the cell leading to its swelling [30]. In addition, damage of the cell membrane as well as cytoplasmic vacuolation in the axons and Schwann cells could be a result of lipid peroxidation [31]. This agrees with the suggestion of Woolf [32], who stated that the first manifestation of cell injury or degeneration is swelling due to accumulation of water, and thus the cytoplasm appears granular. Another study [33] revealed degenerative changes to all cellular components of the hypothalamic neurons of juvenile rabbits after aspartame administration.

Morphometric analysis of the sciatic nerve 12 weeks after receiving aspartame revealed a significant reduction in the g-ratio (axon/fiber ratio). This reduction may be due to decreased axon diameter or an increase in fiber diameter. The increased fiber diameter is most probably caused by irregular thickening or splitting of myelin [34]. In this study, the decreased axon diameter might have been due to compression by the abnormal myelin. Hence, when the morphological changes improved in the Recovery Group, the g-ratio increased again.

The present study demonstrated that the histological changes showed significant improvement 4 weeks after discontinuation of aspartame but did not return to control levels. This agreed with other authors [12] who stated that improvement from aspartame-induced toxicity was gradual and incomplete. Furthermore, free-radical scavengers, including the functional reserve of antioxidants, vitamins, and minerals, could be necessary for neural protection and regeneration [35]. It has also been shown that aspartame metabolites induced amino acid imbalance within the neuron microenvironment, thus producing nerve damage [36,37].

5. Conclusion

The present study shows that long-term administration of aspartame to male albino rats has a harmful effect on the structure of the sciatic nerve. It is recommended to restrict

or avoid the use of aspartame as much as possible, and if its use is necessary, decrease the dose.

Conflicts of interest

None declared.

References

- [1] Sahelian R. Aspartame sweetener side effects, safety, risk and danger. Natural alternatives to this artificial sweetener. Review article. 2014; <http://www.raysahelian.com/aspartame.html>. [Accessed 17 February 2016].
- [2] Soffritti M, Belpoggi F, Manservigi M, Tibaldi E, Lauriola M, Falcioni L, et al. Aspartame administered in feed, beginning pre-natally through life span, induces cancers of the liver and lung in male Swiss mice. *Am J Ind Med* 2010;53:1197–206.
- [3] Fagherazzi G, Vilier A, Saes Sartorelli D, Lajous M, Balkau B, Clavel-Chapelon F. Consumption of artificially and sugar-sweetened beverages and incident type 2 diabetes. *Am J Clin Nutr* 2013;97:517–23.
- [4] Englund-Ögge L, Brantsæter AL, Haugen M, Sengpiel V, Khatibi A, Myhre R, et al. Association between intake of artificially sweetened and sugar-sweetened beverages and preterm delivery: a large prospective cohort study. *Am J Clin Nutr* 2012;96:552–9.
- [5] Saleh AAS. Synergistic effect of N-acetyl cysteine and folic acid against aspartame-induced nephrotoxicity in rats. *Int J Adv Res* 2014;2:363–73.
- [6] El Haliem NGA, Mohamed DS. The effect of aspartame on the histological structure of the liver and renal cortex of adult male albino rat and the possible protective effect of *Pimpinella anisum* oil. *Egypt J Histol* 2011;34:715–26.
- [7] El-Sakhawy M, Saied S. Effect of long term administration of aspartame on the parotid salivary glands of male albino rats. *Int J Adv Res* 2014;2:850–85.
- [8] Ashok I, Sheeladevi R, Wankhar D. Long term effect of aspartame (artificial sweetener) on membrane homeostatic imbalance and histopathology in the rat brain. *Free Rad Antioxidants* 2013;3:S42–9.
- [9] Omar SMM. Effect of aspartame on the frontal cortex of adult male albino rats. A light and electron microscopic study. *Egypt J Histol* 2009;32:346–57.
- [10] Abd El-Samad AA. Light and electron microscopic study on the effect of aspartame on the cerebellar cortex of male albino rat. *Egypt J Histol* 2010;33:419–30.
- [11] Simintzi I, Schulpis KH, Angelogianni P, Liapi C, Tsakiris S. The effect of aspartame on acetylcholinesterase activity in hippocampal homogenates of suckling rats. *Pharmacol Res* 2007;56:155–9.
- [12] Christian B, McConaughy K, Bethea E, Brantley S, Coffey A, Hammond L, et al. Chronic aspartame affects T-maze performance, brain cholinergic receptors and Na⁺,K⁺-ATPase in rats. *Pharmacol Biochem Behav* 2004;78:121–7.
- [13] Hjelle JJ, Dudley RE, Marietta MP, Sanders PG, Dickie BC, Brisson J, et al. Plasma concentrations and pharmacokinetics of phenylalanine in rats and mice administered aspartame. *Pharmacology* 1992;44:48–60.
- [14] Bozzola JJ, Russell LD. *Electron microscopy principles and techniques for biologists*. 2nd ed. Toronto, London: Jones and Bartlett; 1999. p. 16.
- [15] Chomiak T, Hu B. What is the optimal value of the g-ratio for myelinated fibers in rat CNS? A theoretical approach. *PLoS ONE* 2009;4:e7754.
- [16] Williams-Crosby S. Neurodegenerative diseases and aspartame. 2008. <http://www.spice-of-life.com/columns/thesis1.html> [Accessed 17 February 2016].
- [17] Mourad IM. Effect of aspartame on some oxidative stress parameters in liver and kidney of rats. *Afr J Pharm Pharmacol* 2011;5:678–82.
- [18] Camfield PR, Camfield CS, Dooley JM, Gordon K, Jollymore S, Weaver DF. Aspartame exacerbates EEG spike-wave discharge in children with generalized absence epilepsy: a double-blind controlled study. *Neurology* 1992;42:1000–3.
- [19] Parthasarathy JN, Ramasundaram SK, Sundaramahalingam M, Pathinasamy SD. Methanol induced oxidative stress in rat lymphoid organs. *J Occup Health* 2006;48:20–7.
- [20] Abhilash M, Paul MVS, Arghese MVV, Nair RH. Effect of long term intake of aspartame on antioxidant defense status in liver. *Food Chem Toxicol* 2011;49:1203–7.

- [21] Liu PK. Ischemia reperfusion-related repair deficit after oxidative stress: implications of faulty transcripts in neuronal sensitivity after brain injury. *J Biomed Sci* 2003;10:4e13.
- [22] Pragasam V, Kalaiselvi P, Sumitra K, Srinivasan S, Varalakshmi P. Counteraction of oxalate induced nitrosative stress by supplementation of L-arginine, a potent antilithic agent. *Clin Chem Acta* 2005;354:159–66.
- [23] Ebaid H, Samir AE, Bashandy I, Alhazza M, Rady A, El-Shehry S. Folic acid and melatonin ameliorate carbon tetrachloride-induced hepatic injury, oxidative stress and inflammation in rats. *Nutrition Metab* 2013;10:20.
- [24] Blaylock RL. Excitotoxins, neurodegeneration and neurodevelopment. *Med Sentinel J* 1999;4:212–5.
- [25] Ceballos D, Cuadras J, Verdú E, Navarro X. Morphometric and ultrastructural changes with ageing in mouse peripheral nerve. *J Anat* 1999;195:563–76.
- [26] Ying JZ, Tao Z, Ying BZ, Su FY, Qing SW, Li PZ, et al. Effects of acrylamide on the nervous tissue antioxidant system and sciatic nerve electrophysiology in the rat. *Neurochem Res* 2008;33:2310–7.
- [27] Valéria PC, Augusto CV, Marcelo MV, Randy N, Kenneth CM. Diabetic peripheral neuropathies: a morphometric overview. *Int J Morphol* 2010;28:51–64.
- [28] Gawish SA. Morphometric and ultrastructural changes in the sciatic nerve of the albino rat after a long period of immobilization of the knee and ankle joints. *Egypt J Histol* 2004;27:112–27.
- [29] Saito Y, Nishio K, Yoshida Y, Niki E. Cytotoxic effect of formaldehyde with free radicals via increment of cellular reactive oxygen species. *Toxicology* 2005;1:235–45.
- [30] Goljan EF. *Rapid review pathology*. Maryland Heights, MO: Mosby; 2011. p. 360.
- [31] Kumar V, Abbas AK, Fausto N. *Cellular adaptation, cell injury and cell death* (chapter 1). In: Robbins and Cotran pathologic basis of disease. 7th ed. Oxford: Elsevier Saunders; 2008, p. 3.
- [32] Woolf N. *Cell, tissue and disease. The basis of pathology*. 3rd ed. Saunders; 2000. p. 29–38.
- [33] Puica C, Craciun C, Rusu M, Cristescu M, Borsa M, Roman I. *Bulletin, VASVM. Vet Med* 2008;65:424–9.
- [34] El-Derieny EA, Moustafa KA, Soliman GM. The possible protective role of ginseng on the sciatic nerve neuropathy induced experimentally by acrylamide in adult male albino rat: a histological and morphometric study. *Egypt J Histol* 2014;37:350–9.
- [35] Beal MF, Hyman BT, Koroshetz W. Do defects in mitochondrial energy metabolism underlie the pathology of neurodegenerative diseases? *Trends Neurosci* 1993;16:125–31.
- [36] Beck B, Burlet A, Max JP, Stricker Krongrad A. Effects of long-term ingestion of aspartame on hypothalamic neuropeptide Y, plasma leptin and body weight gain and composition. *Physiol Behav* 2002;75:41–7.
- [37] Goerss AL, Wagner GC, Hill WL. Acute effects of aspartame on aggression and neurochemistry of rats. *Life Sci* 2004;67:1325–9.